


ANATOMICAL VARIATION OF THE MAXILLARY FIRST PREMOLAR – CASE REPORT <https://doi.org/10.56238/sevened2025.011-036>

Rosana Maria Coelho Travassos¹, Samuel Nogueira Lima², William José Lopes de Freitas³, Luciane Farias de Araújo⁴, Josué Alves⁵, Adriane Tenório Dourado Chaves⁶, Mônica Maria de Albuquerque Pontes⁷, Alexandre Batista Lopes do Nascimento⁸, Priscylla Gonçalves Correia Leite de Marcelos⁹, Verônica Maria de Sá Rodrigues¹⁰, Priscila Prosini¹¹, Kattyenne Kabbaz Asphora¹² and Ronaldo de Carvalho Raimundo¹³.

ABSTRACT

The present clinical case report describes a rare case of maxillary first premolar with three separate roots prepared with Solla Collors file in a single session on tooth 24. A 26-year-old female patient presented to the dental office (MFB specialized endodontics) in the city of Lauro de Freitas, BA, complaining of painful symptoms in the left maxillary first premolar, tooth #24. On clinical radiographic examination, it was observed that the canal lumen only in the cervical third of the root, the contour of the periodontal ligaments suggested an atypical anatomy with possibly more than 2 canals. Root canal instrumentation was performed using the electronic apical locator at zero: #35.04 (Solla Files) in the vestibular canals and #40.04 in the palatal canal. The filling of the root canal system was performed using the calibrated single cone technique associated with cement, the AH-Plus. The preparation of the root canals with Solla Collors file was concluded, determining an adequate modeling, in teeth with anatomical variation of premolar with three roots.

¹ Doctor in Dentistry and Endodontics
Faculty of Dentistry of Pernambuco

² Doctor of Dental Clinics
Mário Juca University Center

³ Doctor of Dentistry
Faculty of Dentistry of Pernambuco/UPE

⁴ Doctor in Dental Radiology from
Campinas Faculty of Dentistry - Unicamp
Faculty of Dentistry of Pernambuco - UPE

⁵ Doctor in Oral Rehabilitation - FOB- USP
Faculty of Dentistry of Pernambuco

⁶ Doctor in Endodontics
Faculty of Dentistry of Pernambuco

⁷ Doctor of Dentistry and Endodontics
Faculty of Dentistry of Pernambuco

⁸ Doctor in Dentistry and Endodontics
Faculty of Dentistry of Pernambuco and Federal University of Pernambuco

⁹ Doctor in Dentistry
Federal University of Alagoas

¹⁰ Doctor in Dentistry and Endodontics
Faculty of Dentistry of Pernambuco

¹¹ Doctor in Dentistry
University of Pernambuco

¹² Doctor in Dentistry and Endodontics
Faculty of Dentistry of Pernambuco

¹³ Doctor in Maxillofacial Traumatology and Surgery
Faculty of Dentistry of Pernambuco



Keywords: Endodontics. Preparation of the canal. Rotating instruments. Root canal filling.

INTRODUCTION

The variation in the number of roots, canals, root direction, longitudinal depressions of the roots, the various shapes of the pulp cavity, and the problems in visualizing the apical limit by radiographs make the endodontic procedure of these teeth quite challenging. Endodontic success requires a thorough understanding of the anatomy of the root canal. The variation in the number of roots, canals, root direction, longitudinal depressions of the roots, the various shapes of the pulp cavity, and the problems in visualizing the apical limit by radiographs make the endodontic procedure of these teeth quite challenging. (Khan et al. 2024).

The premolars, for the most part, have two roots with 2 channels, however, in some rare cases three roots with three channels can be found, being called "mini molars" which ends up being a great challenge in endodontic treatment. According to the literature, the incidence of maxillary second premolars with three root canals appears to be distributed among specific regions of the world: with the majority being in South America, followed by the Middle East and southern China. (Almeida Gomes, 2009).

An analysis of the dental anatomy on the initial radiograph, as well as special attention to the characteristics of the external anatomy, represent essential requirements to ensure the correct identification of extranumerary canals, although root canal anomalies of the maxillary first premolars have a low prevalence, they must be detected by careful evaluation to avoid possible endodontic failures (Casadei et al., 2020).

The success of an endodontic treatment requires a comprehensive knowledge of root morphology and root canal anatomy along with knowledge of possible morphological variations. Among the most prevalent anatomical alterations, the internal anatomy is the one that generates the most difficulties during the preparation of the root canal, and this fact is largely due to the lack of information on the part of the operator. (Pereira, 2021).

Endodontics, as well as other areas of Dentistry, is in permanent evolution, requiring undergraduate students and professionals to constantly update it, which includes in-depth study and training to adapt to the novelties available in the market. The preparation of the root canal, as a result of the improvement of the alloys involved in the manufacturing process of endodontic instruments, has undergone significant changes in recent decades, considerably altering the way in which the endodont is acted. Controlled memory alloys (CMcontrolled memory) are part of this new generation of NiTi instruments, representing a huge evolutionary leap, significantly modifying the approach and conduction of the technique. Its high flexibility and the heat and surface treatment received during its manufacture have demonstrated safe clinical performance. (Boonchoo et al. 2020).

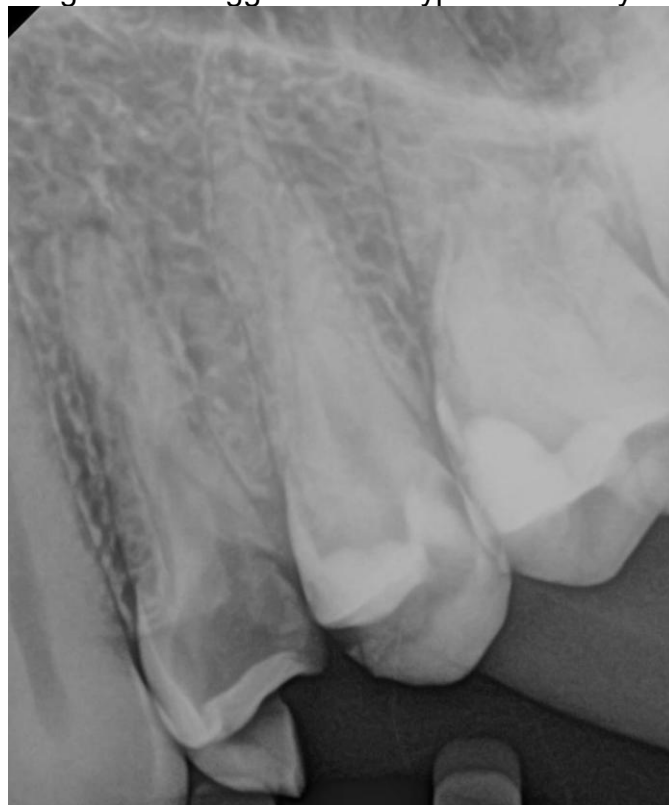The objective of this study was to describe the treatment of maxillary premolar with three separate roots with mechanized instrumentation.

CASE REPORT

A 26-year-old female patient presented to the dental office (MFB specialized endodontics) in the city of Lauro de Freitas, BA, complaining of painful symptoms in the left maxillary first premolar, tooth #24.

On clinical radiographic examination, extensive caries was observed reaching the pulp chamber with loss of the entire distal wall. Regarding the root anatomy, a canal lumen was observed radiographically only in the cervical third of the root, the contour of the periodontal ligaments suggested an atypical anatomy with possibly more than 2 canals. (Figure 1).

Figure 1 - Canal lumen only in the cervical third of the root, the contour of the periodontal ligaments suggested an atypical anatomy.



In the pulp sensitivity test to cold, the patient exhibited a positive and exacerbated response and there were no periapical symptoms (palpation and percussion). After the diagnosis of irreversible pulpitis, the patient was anesthetized using 2% lidocaine with epinephrine 1:100,000 (DFL). Next, the cariated tissue was removed and the distal wall was lifted with direct opalis flow (FGM) resin. Next, coronary access was performed with a

#1014 diamond drill (KG Sorensen) and E8 ultrasound tip (Helse). All treatment was conducted with magnification (alliance microscope).

The initial exploration of the root canals was performed with manual files of the C Pilot type (VDW), and compensatory wear with an E8 ultrasound tip (Helse) in the buccal embouchure. At this point, it has been possible, under magnification, to identify 2 vestibular entrances, one in mesial orientation and the other in distal orientation.

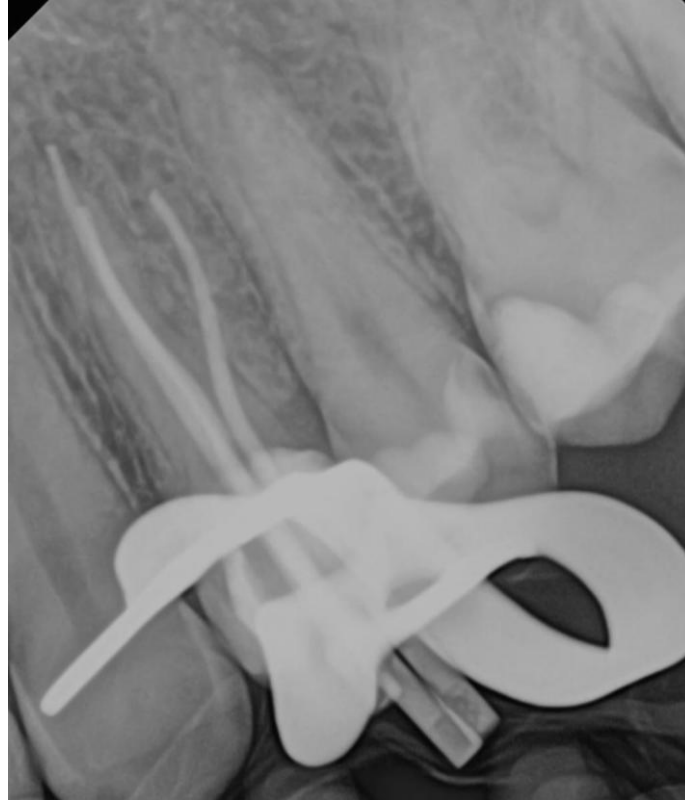
The preparation of the mid-cervical third of the root canals was 17 mm with the 25.09 rotary instrument (solla files), since the apparent length of the tooth was 24 mm. After the preparation of the middle cervical third, a copious irrigation with 2.5% sodium hypochlorite was performed. Then, electronic dentistry with an apical locator from MK Life was performed with manual instrument #15 (dentsply) in the buccal canals and manual instrument #20 in the palatal canal. Measurements of 25 mm in the palatal canal and 24 mm in the buccal canals were obtained.

Root canal instrumentation was performed at zero measurement of the electronic apical locator in the following sequence: 15.04, 20.04, 30.04 and 35.04 (Solla Files) in the vestibular canals and 25.04, 35.04 and 40.04 (Solla Files) in the palatal canal. At each instrument change, a copious irrigation with 2.5% sodium hypochlorite was performed.

To remove the Smear Layer, 17% EDTA was used in 3 cycles with sonic shaking for 30 seconds followed by 2.5% sodium hypochlorite in 3 cycles with sonic shaking for 30 seconds in the 3 conduits, as a final irrigant, saline solution was used

The clinical adaptation of the main gutta-percha cones was confirmed on X-rays with a mesio-radial view, with an overlap of the palatine root with the mesiobuccal root (Figure 2). At that time, a new radiographic odontometry was performed, confirming the working length of the two aforementioned canals.

Figure 2 – Clinical and radiographic adaptation of the main cones of gutta-percha.



The filling of the root canal system was performed using the calibrated single cone technique associated with cement, the AH-Plus. The gutta-percha was cut with a thermocompactor (WAK) 1mm below the inlets, and the gutta-percha compaction was done with Schilder condensers.

Radiography of the ductus filling was performed, determining the overlap of the mesiobuccal and palatal canals (Figure 3). Thus, radiographic imaging was performed using the disto-radial Clark technique, observing the three separate roots (Figure 4).

The access cavity was cleaned with ultrasound and 70% alcohol and shielded with flow-type resin at the inlets and floor, the rest of the cavity was filled with light-curing CIV (vococo).

Figure 3 – Mesium -radial radiography - the overlap of the mesiobuccal and palatine canals.

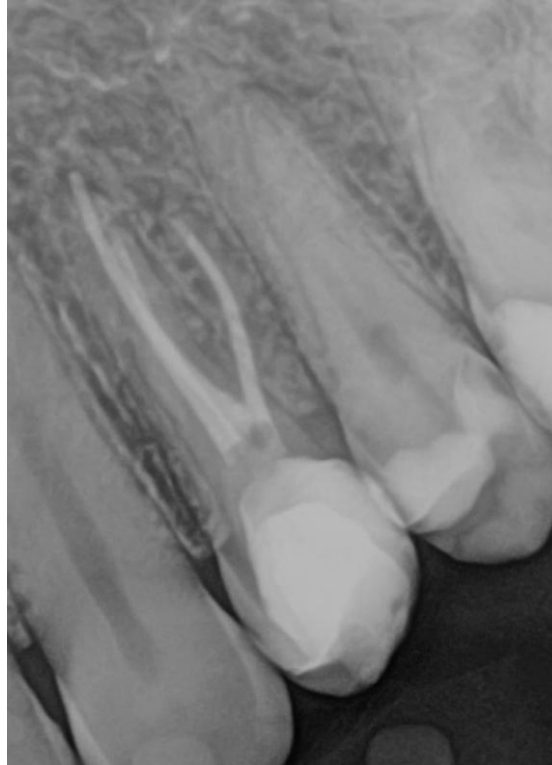
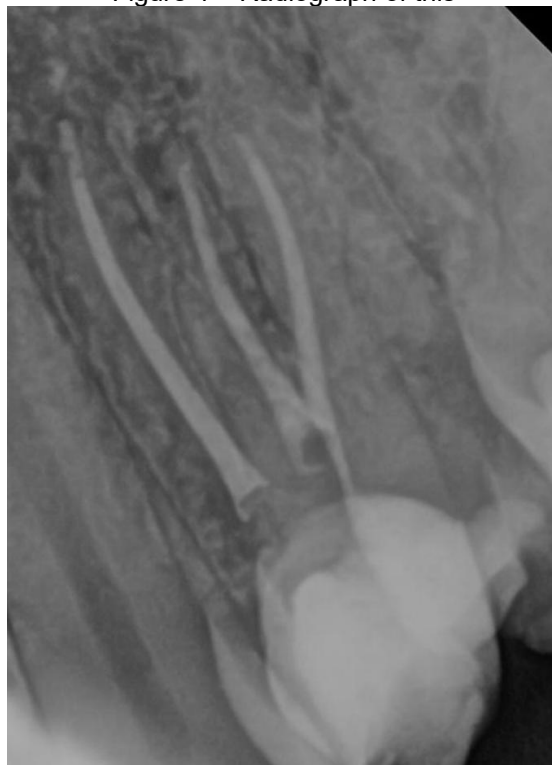
Figure 4 – Radiograph of this



DISCUSSION

The present report describes a first premolar with 3 roots and 3 root canals that belong to infrequent anatomical variations, and a different look is required from the dentist at the time of case resolution, as its level of difficulty increases. In this way, the report to the

scientific community is important so that it serves as a basis for consultation. Future research involving controlled studies would provide a more comprehensive understanding of treatment approaches for complex endodontic cases.

A complementary angled radiographic take allows the dissociation of the canals and, consequently, their radiographic visualization, in cases where the roots are fused, if the three roots are separated, the radiographic image is similar to that of a maxillary first molar. Because of this anatomical similarity, maxillary premolars are often referred to as minimolars. (Mathew et al. 2015). In this case, the three root canals were observed separately, with disto-radial incidence.

It is important to observe the floor of the pulp chamber during opening, as it may show traces of the existing types of root canals. If there is only one canal, it is in the center of the pulp chamber and is relatively easy to find. If a hole is found far from the center, there is a greater chance that there will be another on the opposite side. The farther away the entrances to the canals, the greater the chance that they are separated by their entire length (Martins, 2011).

The introduction of nickel-titanium (NiTi) mechanical instruments has drastically changed clinical endodontics in recent decades. Before NiTi, it was necessary to use more instruments to create an optimal root canal shape, and many approaches, sequences, and techniques have been developed over the years. Recently, NiTi endodontic instruments have undergone a number of changes brought about by design modifications, surface treatments, and heat treatments to improve their root canal preparation results and reduce the risks associated with root canal preparation during root canal treatment. Heat treatment is one of the most fundamental approaches to improving the fatigue resistance and flexibility of NiTi endodontic instruments. In addition, new kinematics have been developed to offer greater safety and efficiency. (Grande et al. 2023).

It is considered necessary for the operator to have scientific knowledge and manual skill to perform the necessary operative steps that have a higher learning curve. Factors such as a good prognosis, longevity of the treatment and, above all, the health and function of the tooth in question must be achieved. (Travassos et al. 2024). Familiarity with the systems, the ability to use them, and knowledge of best practices are essential to ensure effective and safe retreatment. Continuous training, along with updating on the latest techniques and technologies, is a valuable approach for professionals seeking high-quality results. In the present case, the operator has been a specialist in endodontics for more than 10 years and with a lot of skill in performing instrumentation with files that have been launched in the dental market.

The knowledge and understanding of the morphological alterations and anatomical variations present in the root systems, as well as the use of minimally invasive instruments, maintaining the original shape of the pulp space, preserving as much of the remaining tooth structure as possible, enabled satisfactory results, presenting success in the endodontic treatment of the upper premolar, can influence and contribute significantly to an endodontic treatment. Therefore, in this case, it was opted for the Solla system magnets, launched on the market with high flexibility and low taper characteristics

The determination of a correct working length during root canal preparation is essential to promote the repair of periapical tissues. The most widely used method to date for determining odontometry is radiographic. However, due to the limitations of this technique – two-dimensional image of three-dimensional structure, image distortion, overlapping of anatomical structures, exposure to radiation, and errors in interpretation, there is an increasing search for alternatives that help in determining the ideal working length. Therefore, in this study, the apical foraminal locator was used.

Endodontic cement is a plastic material that helps in the filling of the root canal, as it aims to fill and seal the space between the gutta-percha cones and between them and the dentin walls. It is of great importance that the cement is easy to be taken to the canal, has a satisfactory working time and that it has satisfactory physicochemical properties for a correct sealing, and it is essential that it is well tolerated by the tissues of the periapex. (Souza et al., 2001). In the present case, AH-Plus cement was used.

CONCLUSION

The preparation of the root canals with Solla Collors file was concluded, determining an adequate modeling, in teeth with anatomical variation of premolar with three roots.

REFERENCES

1. Almeida-Gomes, F., de Sousa, B. C., de Souza, F. D., dos Santos, R. A., & Maniglia-Ferreira, C. (2009). Unusual anatomy of maxillary second premolars. *European Journal of Dentistry*, 3(2), 145–149.
2. Boonchoo, K., Leelataweewud, P., Yanpiset, K., & Jirarattanasopha, V. (2020). Simplify pulpectomy in primary molars with a single-file reciprocating system: A randomized controlled clinical trial. *Clinical Oral Investigations*, 24(8), 2683–2689.
3. Casadei, B. A., Lara-Mendes, S., Barbosa, C., Araújo, C. V., de Freitas, C. A., Machado, V. C., & Santa-Rosa, C. C. (2020). Access to original canal trajectory after deviation and perforation with guided endodontic assistance. *Australian Endodontic Journal*, 46(1), 101–106.
4. Grande, N. M., Castagnola, R., Minciocchi, I., Marigo, L., & Plotino, G. (2023). A review of the latest developments in rotary NiTi technology and root canal preparation. *Australian Dental Journal*, 68(1), 24–38.
5. Khan, D., Ahmed, A., Sabana Haq, S., et al. (2024). Endodontic treatment of upper first premolar with 3 canals – Case report. *Journal of Rawalpindi Medical College*, 28(2), 352–355.
6. Martins, J. N. R. (2011). Primeiro pré-molar superior com três canais: diagnóstico e tratamento – quatro casos clínicos. *Revista Portuguesa de Estomatologia, Medicina Dentária e Cirurgia Maxilofacial*, 52(1), 43–51.
7. Mathew, J., Devadathan, A., Syriac, G., & Shamini, S. (2015). Root canal treatment of a maxillary first premolar with three roots. *Journal of Pharmacy and Bioallied Sciences*, 7(6), 746–748.
8. Pereira, C. (2021). Tratamento endodôntico em sessão única de pré-molar superior com três canais: Relato de caso (Monografia de especialização). Faculdade Sete Lagoas, Salvador.
9. Souza, V., Nery, M. J., Rodrigues, R. R., Dezan Júnior, E., Scanacavacca, P., & Munhoz, A. C. (2001). Avaliação do selamento marginal apical obtido com alguns cimentos endodônticos. *Arquivos de Ciências da Saúde UNIPAR*, 5(1).
10. Travassos, R. M., et al. (2024). Preparo do canal radicular do canino superior com Lima Solla Colors rotatórias. *Brazilian Journal of Implantology and Health Sciences*, 6(11), 334–341.