


**FACTOR V LEIDEN MUTATION AND PROTHROMBIN GENE ASSOCIATED WITH INTRACRANIAL VENOUS THROMBOSIS: A CASE REPORT** <https://doi.org/10.56238/sevened2025.008-038>

**Renan da Silva Bentes<sup>1</sup>, Marcelo Caetano Hortegal Andrade<sup>2</sup>, Matheus Mychael Mazzaro Conchy<sup>3</sup>, Elias José Piazzentin Gonçalves Junior<sup>4</sup>, Tauaní Coelho Nabuco de Araújo Souza<sup>5</sup>, Lúcio Elber Licarião Távora<sup>6</sup> and Márcio Tiago de Oliveira Barbosa<sup>7</sup>.**

**ABSTRACT**

Intracranial venous thrombosis is an uncommon event with high morbidity and mortality. This article aims to present a case of intracranial venous thrombosis associated with mutation of factor V Leiden and mutation in the prothrombin gene after contraceptive use that culminated in ischemic optic neuropathy and permanent total bilateral amaurosis. Early diagnosis and treatment are essential for patient survival and relevant genetic screening for clinical counseling and, thus, to avoid new thrombotic episodes of great clinical repercussion in female individuals.

**Keywords:** Intracranial Venous Thrombosis (TVI). Factor V Leiden (MFVL) mutation. Mutation in the Prothrombin Gene (PM). Ischemic optic neuropathy (ION). Combined contraceptives (ACO).

---

<sup>1</sup> General Practitioner  
Federal University of Roraima - UFRR  
Email: reenan.bentes@hotmail.com

<sup>2</sup> General Practitioner  
Federal University of Roraima – UFRR  
E-mail: mchamv@hotmail.com

<sup>3</sup> General Practitioner  
Federal University of Roraima – UFRR  
E-mail: matheusmazzaro03@gmail.com

<sup>4</sup> General Practitioner  
Federal University of Roraima – UFRR  
E-mail: eliasjose1994@hotmail.com

<sup>5</sup> Medical student – 4th year  
Nove de Julho University – UNINOVE  
E-mail: tauaniaraujo@gmail.com

<sup>6</sup> Gynecology and Obstetrics Specialist  
Federal University of Roraima – UFRR  
E-mail: luciano.tavora@hotmail.com

<sup>7</sup> Full Member on the Brazilian Society of Neurosurgery  
Master in Health Science – AC Carmargo Cancer Center  
Specialization in Endoscopic Spine Surgery – FMRP – USP  
Specialization in Neuro-oncology Sírío Libanês  
E-mail: marciotob@ig.com.br

## INTRODUCTION

Intracranial venous thrombosis (IVT) is a disease of the dural sinuses that includes the clinical picture of headache, intracranial hypertension, jet vomiting, focal neurological deficit and seizure.<sup>1,2</sup>

The predominant gene mutations linked to TVI are hereditary thrombophilias, of which the three most common include factor V Leiden (MFVL) mutation, prothrombin gene (MP) mutation, and methylenetetrahydrofolate reductase homozygosis.<sup>3, 4</sup> In addition, the continuous use of oral contraceptives (OC) is a well-established risk factor for the etiology of thrombotic events, since it can cause a state of hypercoagulability, which is one of the components of Virchow's triad.<sup>5</sup>

TVI can cause ischemic optic neuropathy (ION) and permanent total bilateral amaurosis<sup>6</sup>, and its etiology may be linked to MFVL and PM.<sup>7-9</sup> BED

Thus, this scientific description aims to present an unusual case of TVI in a young female patient, continuous user of OC and carrier of MFVL and PM with severe sequelae of ON.

## CASE REPORT

This study was approved by the Research Ethics Committee via Plataforma Brasil with Opinion Number 3.702.345 and Certificate of Presentation of Ethical Appreciation of 18093719.6.0000.5302.

A 22-year-old female patient, OCO user, was admitted to the General Hospital of Roraima (HGR/RR) complaining of intense holocranial headache with no signs of meningeal irritation and jet vomiting. However, the patient began to present vertigo associated with bilateral partial amaurosis, with little change in postural position and no antalgic attitude, but with gait difficulty, with progressive evolution and worsening, associated with the appearance of hemiparesis in the left dimension, complete and disproportionate with crural predominance, with ipsilateral nasolabial fold and motor strength grade 2 in the left lower limb and grade 3 in the left upper limb compromised. In addition to dysphasia.

The patient was referred to the emergency room of the HGR on the third day of symptoms after intensification of the insidious headache, decline in general condition and appearance of bilateral partial amaurosis, left hemiparesis, alteration of facial expression and worsening of jet vomiting episodes. Direct fundoscopy showed bilateral papilledema. Laboratory tests of blood count, renal function, liver injury, electrolytes, summary urine examination and coagulogram without noteworthy alterations.

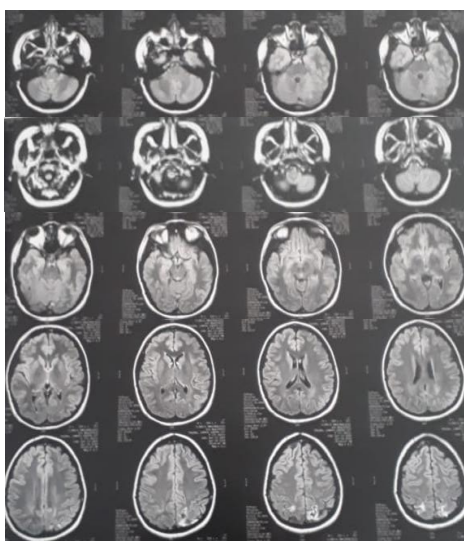
She was hospitalized with a level of consciousness of 13 (eye opening = 3; best verbal response = 5; best motor response = 5) on the Glasgow Coma Scale at admission, and was referred to the Intensive Care Unit (ICU) of the General Hospital of Roraima (HGR/RR) due to imminent severity of the condition and whose basic treatment consisted of full anticoagulation with enoxaparin due to initial propaedeutic investigation with arterial magnetic resonance angiography of intracranial vessels having found TVI extensive sagittal, transverse, and sigmoid sinuses on the right; Osmotic diuretic mannitol was also administered due to clinical and radiological evidence of intracranial hypertension.

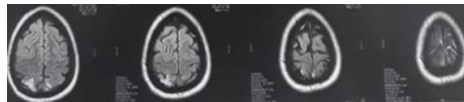
The possibility of surgical decompression to recover the visual deficit was evaluated, but the opinions of the neurosurgery and ophthalmology specialties did not see any benefits, since both radiologically and from the clinical point of view there were evident signs of irreversible ON.

A genetic panel was carried out with research for hereditary thrombophilias, which was positive for MFVL and MP. She denied a previous pathological history of comorbidities, was previously healthy, but reported regular use of combined oral contraceptives (IUMI, ethinyl estradiol and drospirenone).

After six days of hospitalization, the patient was discharged from the ICU and was sent to the ward for clinical follow-up. In this sector, the patient began to show a slight improvement in the clinical and neurological condition during pharmacological therapeutic treatment, expressed by the reduction of paresis, restoration of the level of consciousness (Glasgow 15) and absence of dysphasia, although he maintained permanent total bilateral amaurosis.

Figure 1: Venous Resonance Angiography of Control Intracranial and Cervical Vessels about 60 days after the TVI event.

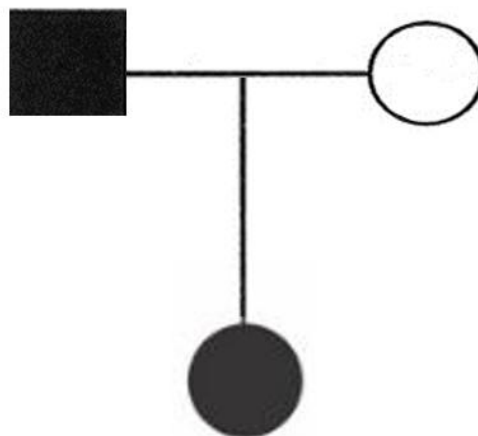




After approximately 60 days of hospitalization, in which imaging exams showed recanalization of practically all thrombi, complete bilateral amaurosis, and significant improvement of holocranial headache, the patient was discharged from the hospital under these conditions for outpatient clinical follow-up at the neurology service, physical rehabilitation through physical therapy, occupational and psychological therapy, and continuous prophylactic anticoagulation (5 mg per day).

The first magnetic resonance imaging examination of the brain showed signs of extensive venous sinus thrombosis, mainly affecting the superior sagittal sinus and transverse venous sinuses, right sigmoid and jugular vein, associated with signs of subarachnoid hemorrhage in the supratentorial compartment (complicated TVI) and bilateral edema of the optic nerves (suggestive of congestion process).

Figure 2. Heredrogram demonstrating patient and family members with FFM.



After 60 days, venous resonance angiography of intracranial and cervical vessels (Figure 1) of control showed complete recanalization of the transverse and right sigmoid sinuses, as well as of the internal jugular vein, in relation to the reference studies performed at admission. Signs suggestive of cervical hematoma on the right were also observed, compressing the internal jugular vein in its most inferior portion, but without collapse.

The patient's father tested positive for MFVL, as shown in Figure 2. The patient, in addition to this mutation, also tested positive for PM.

## DISCUSSION

The genetic predisposition to hemostasis disorders is called hereditary thrombophilias. The hereditary deficiency of endogenous anticoagulants such as protein C, protein S, and antithrombin have been recognized for decades. A fundamental step was taken with the discovery of resistance to activated protein C (PCA) and factor V Leiden. Subsequently, the prothrombin polymorphism G20210A was described as an important cause of familial thrombophilia.<sup>4:10-11</sup>

In addition, MFVL and PM, when present concomitantly with the use of OC, strongly predispose to thrombotic events such as TVI.<sup>12-14</sup>

The patient in the case reported here was positive for FFM and PM and after using combined OC, progesterone and estrogen, she developed TVI and NOI, although even after treatment with adequate anticoagulation, she presented complete and permanent bilateral amaurosis as a sequela. After seven years of outpatient clinical follow-up, there was no recurrence of the case and it was recommended to discontinue OC at the time of diagnosis of thrombophilia.

Thus, the present case exposes the importance of genetic investigation of MFVL and PM in patients with TVI as well as prior and adequate counseling regarding the continuous use of ACO. Likewise, they should be followed up clinically for ION and the possibility of permanent amaurosis.

## REFERENCES

1. Allroggen, H., & Abbott, R. J. (2000). Cerebral venous sinus thrombosis. *Postgraduate Medical Journal*, 76(891), 12–15. <https://pmc.ncbi.nlm.nih.gov/articles/PMC1741463/>
2. Weih, M., et al. (2000). Hereditary thrombophilia in cerebral venous thrombosis. *Cerebrovascular Diseases*, 10, 161–162. <https://karger.com/ced/article-abstract/10/2/161/56242/Hereditary-Thrombophilia-in-Cerebral-Venous>
3. Bertina, R. M., et al. (1994). Mutation in blood coagulation factor V associated with resistance to activated protein C. *Nature*, 369, 64–67. <https://www.nature.com/articles/369064a0>
4. Poort, S. R., et al. (1996). A common genetic variation in the 3'-untranslated region of the prothrombin gene is associated with elevated plasma prothrombin levels and an increase in venous thrombosis. *Blood*, 88, 3698–3703. <https://ashpublications.org/blood/article/88/10/3698/125040/A-common-genetic-variation-in-the-3-untranslated>
5. Dentali, F., Crowther, M., & Ageno, W. (2006). Thrombophilic abnormalities, oral contraceptives, and risk of cerebral vein thrombosis: A meta-analysis. *Blood*, 107(7), 2766–2773. <https://ashpublications.org/blood/article/107/7/2766/132046/Thrombophilic-abnormalities-oral-contraceptives>
6. Coutteel, C., et al. (1991). Bilateral blindness in cavernous sinus thrombosis. *International Ophthalmology*, 15, 163–171. <https://pubmed.ncbi.nlm.nih.gov/2050471/>
7. Gogu, A. E., et al. (2021). MTHFR gene polymorphisms and cardiovascular risk factors, clinical-imagistic features and outcome in cerebral venous sinus thrombosis. *Brain Sciences*, 11, 23. <https://www.mdpi.com/2076-3425/11/1/23>
8. Idiculla, P. S., et al. (2020). Cerebral venous thrombosis: A comprehensive review. *European Neurology*, 83, 369–379. <https://karger.com/ene/article/83/4/369/125770/Cerebral-Venous-Thrombosis-A-Comprehensive-Review>
9. Saposnik, G., et al. (2024). Diagnosis and management of cerebral venous thrombosis: A scientific statement from the American Heart Association. *Stroke*, 55, e77–e90. <https://www.ahajournals.org/doi/10.1161/STR.0000000000000456>
10. Carvalho, E. B., et al. (2005). Rastreamento familiar do fator V de Leiden: A importância da detecção de portadores heterozigotos. *Revista Brasileira de Hematologia*, 27(2), 83–86. <https://www.scielo.br/j/rbhh/a/YP8BjmnK7V8gtPhK6wPt4Rj/?lang=pt>
11. Kalafatis, M. (1995). Characterization of the molecular defect in factor V R506Q. *Journal of Biological Chemistry*, 270, 4053–4057. <https://pubmed.ncbi.nlm.nih.gov/7876154/>
12. Martinelli, I., et al. (1998). High risk of cerebral-vein thrombosis in carriers of a prothrombin-gene mutation and in users of oral contraceptives. *The New England Journal of Medicine*, 338, 1793–1797. <https://pubmed.ncbi.nlm.nih.gov/9632445/>

13. Deschien, M. A., et al. (1996). Coagulation studies, factor V Leiden, and anticardiolipin antibodies in 40 cases of cerebral venous thrombosis. *Stroke*, 27, 1724–1730. <https://www.ahajournals.org/doi/full/10.1161/01.STR.27.10.1724>
14. De Bruijn, S. F., et al. (1998). Case-control study of risk of cerebral sinus thrombosis in oral contraceptive users and in carriers of hereditary prothrombotic conditions. *BMJ*, 316, 589–592. <https://www.bmj.com/content/316/7131/589>