


**ALOPECIA X IN GERMAN SPITZ RESPONSIVE TO ORCHIECTOMY
ASSOCIATED WITH THE USE OF MELATONIN: CASE REPORT**

 <https://doi.org/10.56238/sevened2024.037-182>

Ana Paula Dossena¹, Nicole Amoêdo Luvison², Ketlin Milena Zardin³, Camille Moreira Bergamo Barros⁴, Gabriela Victoria Araújo Saraiva⁵, Dreyd Rodrigues Medeiros⁶, Barbara Fernandes Werneck Teixeira⁷, Édios Meurer Lana da Silva⁸, Carolina Aires Martins⁹ and Luanda Ferreira Cipriano¹⁰.

¹ Especialista em Dermatologia Veterinária
Unesp -SP

luandafcipriano@gmail.br/

<https://orcid.org/0000-0002-8246-3257/>

<http://lattes.cnpq.br/6176296921118786>

² Graduanda em Medicina Veterinária

Universidade de Caxias do Sul- UCS

naluvison@ucs.br

<https://orcid.org/0009-0005-5783-8810>

<http://lattes.cnpq.br/7395426062661654>

³ Universidade de Caxias do Sul- UCS

ketlinkolling@gmail.com

<https://orcid.org/0009-0004-1683-2271>

<http://lattes.cnpq.br/0685734131130293>

⁴ Graduanda em Medicina Veterinária

União Pioneira de Integração Social- UPIS

bergamovetz@gmail.com

0009-0000-6688-3000

<https://lattes.cnpq.br/9445983420853659>

⁵ Graduanda em Medicina Veterinária

gvictoriasaraiva@gmail.com

61 993068888

0009-0002-0616-0956

Universidade Católica de Brasília - UCB

Lattes: <https://lattes.cnpq.br/9933238062460353>

⁶ Graduanda em Medicina Veterinária

drmedeiro@me.com

0009-0002-5714-9642

<https://lattes.cnpq.br/9504913789155844>

⁷ Graduanda em Medicina Veterinária

barbarafwt@gmail.com

Universidade Católica de Brasília- UCB

<https://orcid.org/0009-0008-7426-4769>

<https://lattes.cnpq.br/1011296974890263>

⁸ Graduando em Medicina Veterinária

União Pioneira de Integração Social- UPIS

edmeurerls@gmail.com

0009-0002-0311-5834

<https://lattes.cnpq.br/6899580204036046>

⁹ Graduanda em Medicina Veterinária

carol.aires@gmail.com

0009-0008-4152-0594

Universidade Católica de Brasília -UCB

Lattes: <https://lattes.cnpq.br/8985736732153179>

¹⁰ Doutora em Medicina Veterinária

Unesp-SP

luanda.cipriano@unesp.br

ABSTRACT

Alopecia X is a dermatological disorder that mainly affects Nordic breed dogs. Its cause is not completely clear. Alopecia X is characterized by its non-inflammatory aspect, being similar to endocrine-based dermatopathies. The main lesions are progressive hair loss in the affected areas, being less pronounced on the head and distal extremities of the limbs in more advanced cases. This study aims to report a case of alopecia X in a male, uncastrated German Spitz dog. At the first visit, an initial case of bilateral symmetrical alopecia was observed on the caudal side of the thighs and perineum, without pruritus, macroscopic signs of inflammation and clinical signs of systemic diseases. The patient underwent additional tests (including trichogram, skin scraping, direct ectoparasite screening and blood profile) in which parasitic and systemic diseases were ruled out. Based on clinical aspects, racial predisposition and exclusion of systemic causes, the diagnosis of alopecia X was considered. The treatment of choice was orchiectomy associated with the use of Melatonin, initially for 3 months. After 90 days of treatment, partial regrowth of the alopecic areas was observed, as well as a reduction in the area without hair, with return of primary and secondary hairs in the affected region. It is concluded in this case that the choice of orchiectomy associated with the use of melatonin was effective in improving the dermatological condition, and can be used as an ally.

Keywords: Treatment of alopecia. German Spitz. Melatonin. Dermatology. Dogs.

INTRODUCTION

Alopecia X is so named because its cause is not fully understood (VENÂNCIO et al., 2016). It is characterized by mainly affecting dogs of Nordic breeds, and clinically by bilateral and symmetrical hair loss, and may be associated with melanoderma, especially affecting the cervical, dorsal and perianal regions and sparing the distal region of the limbs and head. (CARVALHO et al., 2023).

Its etiopathogenesis is not fully understood, and several studies are underway to seek further clarification about its cause. Among them, the theory of adrenal hyperplasia syndrome, the theory of growth hormone deficiency and the theory of hypercortisolemia are cited in the literature. Due to its characteristics that resemble endocrine-based dermatopathies, theories about the causes of alopecia X consider that it may be related to hormonal changes, both systemic and local (BAPTISTA, 2018). The possibility of a genetic cause and factors that act directly on the receptors of hair follicles are the targets of more recent studies (VENÂNCIO et al., 2016).

Several nomenclatures have been used for this alteration, which is currently called alopecia X, among them we can mention pseudo-cushing, congenital adrenal hyperplasia syndrome, growth hormone-responsive alopecia and sterilization-responsive dermatosis (ADAMO, 2018).

The variation in nomenclatures is due to the fact that this pathology presents varied responses to different therapeutic alternatives instituted in animals with it, in search of the possible causes of this condition (PASSATUTTO AND JÚNIOR, 2021).

Clinical signs are limited to local changes in skin areas, characterized by the absence or decrease of hair in a bilateral, symmetrical manner, of non-inflammatory origin and generally without associated pruritus. Affected animals may have dry skin, hair that easily comes off the skin and melanoderma (PASSATUTTO and JÚNIOR, 2021). Alopecia usually affects the caudomedial aspect of the hind limbs, perineum, base of the tail, and may extend to the trunk, sparing the head and distal thirds of the limbs (HORTA et al, 2021), a characteristic that is considered almost pathognomonic of the disease (GODIM and ARAÚJO, 2020).

LITERATURE REVIEW

DIAGNOSIS

Various criteria have been discussed to arrive at the diagnosis of alopecia X, which is made by excluding other diseases that present with a similar condition, and is strongly influenced by the racial predisposition and characteristics of the most affected animals:

breed, age group (young animals between one and five years old), location of the alopecic areas and the absence of systemic diseases, such as endocrinopathies (BAPTISTA, 2018).

Hormonal tests allow the exclusion of endocrine diseases such as hyperadrenocorticism and hypothyroidism for a differential diagnosis, as these diseases mimic skin changes that occur in alopecia X (HORTA et al, 2021). Skin histopathology can be performed as an auxiliary exam, but it is not possible to differentiate alopecia X from other endocrine diseases. Microscopic findings generally show few small bulbs in anagen, epidermal hyperpigmentation and the presence of “flame follicles”. However, these are also commonly observed findings in other endocrinopathies (BAPTISTA, 2018).

TREATMENT

A variety of treatments have been tested and used in cases of alopecia X with varying therapeutic success. Among them, we can mention castration, melatonin, trilostane, deslorelin, microneedling, among others, with castration, melatonin and trilostane currently being the most commonly used (BAPTISTA, 2018). It is also recommended to promote hydration of the skin and remaining coat, due to the intense secondary skin dryness in the affected areas (GONDIM and ARAÚJO, 2020).

Sterilization

In intact dogs, castration is cited as the first-choice treatment, since many dogs have had their hair grow back for years or even permanently after regulating hormone concentrations (VENÂNCIO, 2016).

Studies indicate that castration can result in 75% of hair regrowth due to the reduction in serum concentrations of sex hormones (ADAMO, 2018).

Melatonin

Melatonin comes in second place as the most recommended, with success and hair regrowth rates of around 40%. Studies suggest that some plasma and dermal enzymes act with hyperactivity and degrade melatonin in animals with alopecia X, a fact that is supported by the improvement in these animals after using it in treatment (HORTA, 2021).

CASE REPORT

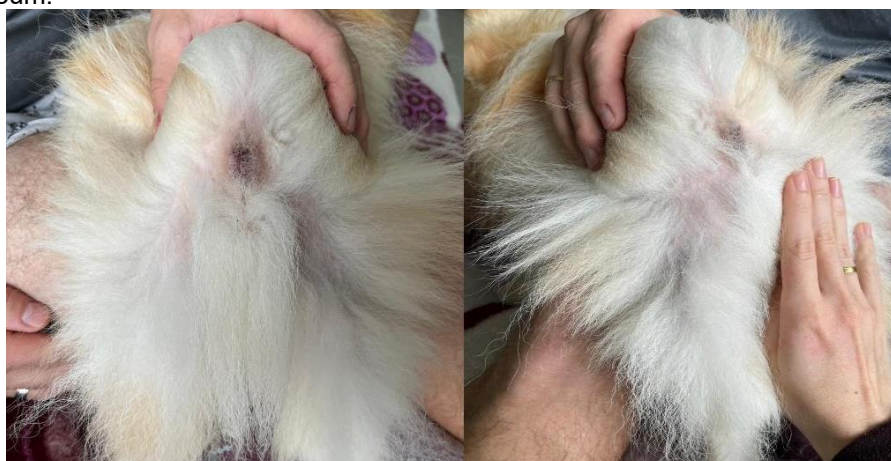A male, unneutered, German Spitz dog, aged one year and 11 months, was seen at Pet Me Au in Criciúma/SC, after being observed drying off after bathing that he had areas of

hair thinning on the caudal side of his thighs, bilaterally, on April 24, 2024. The owner was notified and a dermatological consultation was requested.

Clinically, the animal appeared well, alert, with normal color of the mucous membranes, normal hydration, rectal temperature of 38.1°C, normal pulse, cardiac and pulmonary auscultation without alterations, palpable lymph nodes did not show any enlargement.

Dermatological evaluation revealed primary hair loss and hair thinning on the caudal side of the thighs and bilateral perineal area. The rest of the body was inspected and did not show any other areas of alopecia or other alterations. The skin showed no signs of inflammation, such as redness or crusting, and was normal in color and appearance (figure 1).

Figure 1: Images of the patient presenting bilateral symmetrical hair thinning on the caudal aspect of the thighs and perineum.



Source: personal archive.

After the evaluation, the owner was asked for authorization to perform additional tests: complete blood count, albumin, ALT, creatinine, cholesterol (total and fractions), cortisol (immunofluorescence), triglycerides, TSH (immunofluorescence) and free T4 (chemiluminescence), in addition to skin cytology and trichogram, in order to rule out signs of endocrine diseases that are incriminated in cases of alopecia (table 1).

The skin cytology exam was performed by the veterinarian after a consultation at Pet Me Au, where secondary bacterial infection was ruled out and it was negative for mange and fungi by the direct research method. The trichogram showed that many hairs appeared split in their longitudinal direction, characterizing trichoptilosis.

Table 1: Results of additional laboratory tests.

Exam Result Reference	Exam Result Reference	Exam Result Reference
BLOOD COUNT		

Red blood cells	6,88 / μ L	5,5 a 8,5 x 1.000.000
Erythroblasts	0 %	0 a 5
Hematocrit	44 %	37 a 55
Hemoglobin	14,9 g/dL	12,0 a 18,0
V.G.M	63,95 fL	60 a 77
C.H.G.M.	33,86 g/dL	32 a 36
R.D.W.	12,4 %	10 a 15
P.P.T	7,0 g/dL	6,0 a 8,0
PLATELETS	366.000 / μ L	200.000 a 500.000
LEUKOGRAM		
Leukocytes	8.220 / μ L	6.000 a 17.000
Rods	0 / μ L	0 a 300
Segmented	6.247 / μ L	3.000 a 11.500
Lymphocytes	1.480 / μ L	1.000 a 4.800
Monocytes	0 / μ L	150 a 1.350
Eosinophils	493 / μ L	100 a 1.250
Basophils	0 / μ L	0 a 100
BIOCHEMISTS		
Albumin	2,93 g/dL	2,6 a 3,3
ALT	52,6 U/L	10 a 88
Total cholesterol	179 mg/dL	125 a 270
HDL	162 mg/dL	33 a 120
LDL	12 mg/dL	31 A 71
Cortisol	2,22 mcg/dL	2,0 a 6,0 mcg/dL
Creatinine	1,08 mg/dL	0,5 a 1,5
Triglycerides	27,0 mg/dL	20 a 112
TSH	<0,25 ng/mL	< 0,5 ng/mL
Free T4	0,58 ng/dL	0,32 a 1,69 ng/dL

Given the area of hair thinning and dull fur, local hydration with Hidrapet Skin On spray was prescribed (one spray on each thigh in the affected areas, every 7 days), in order to protect the skin barrier that was exposed without fur, until the results of the blood tests were available for greater diagnostic accuracy and choice of the most appropriate treatment.

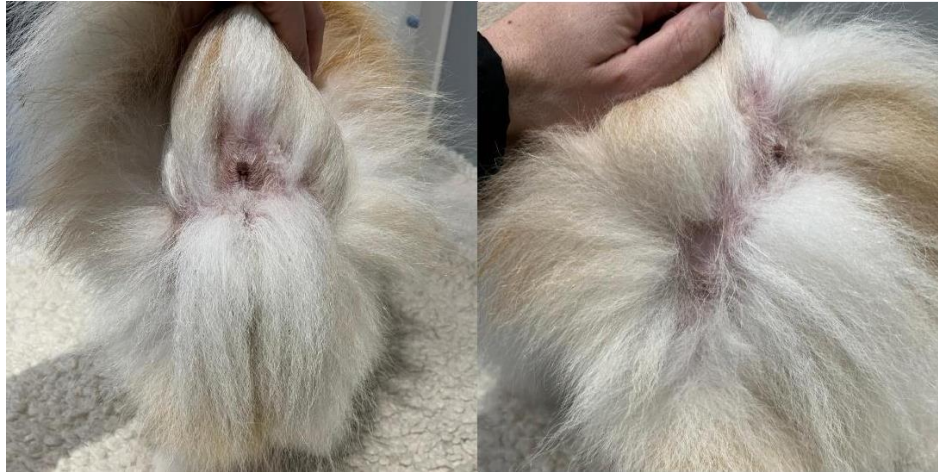After accessing the results of the complementary blood tests that were all within normal limits, in addition to the fact that the skin scraping had been negative for mange and fungi, and taking into account the German Spitz breed and the clinical condition of the animal that showed no signs of systemic diseases, as well as the location of the alopecia, the diagnosis of alopecia X was considered.

When choosing the treatment, the first step was to indicate orchiectomy, which the owner had been considering important for some time, even before the diagnosis. The procedure was performed uneventfully on May 7, 2024. The treatment was combined with the use of melatonin at a dose of 3 mg/animal every 12 hours for at least 3 months, in addition to maintaining the use of hydration after baths every 7 days.

The owner adhered to the treatment, and the animal returned weekly for routine baths, where it was possible to monitor the progress of the treatment. After 90 days, partial

hair regrowth and an increase in primary hair in the alopecic areas were observed (figure 2).

Figure 2: images of the alopecic areas showing partial hair regrowth after 90 days of treatment. Source: personal archive.



Given the partial positive result of therapeutic response, the use of melatonin was extended for another 2 months, together with the Qpelo food supplement to aid in hair growth, until further instructions.

The patient is currently undergoing treatment with the medications mentioned above, and will be reassessed after this period to see if he will need other therapeutic resources such as microneedling. The treatment has been administered without complications, and the patient is in good general condition and showing gradual improvement in his hair.³

CONCLUSION

The increased popularity of the German Spitz breed has led to an increase in cases of alopecia X in veterinary clinics, a fact that has sparked several lines of study to further clarify its cause and treatment.

According to the literature, alopecia X is most commonly seen in Pomeranians, especially in young, unneutered males between 1 and 5 years old (MELLO et al, 2022). In the present case, the patient falls within the most affected breed standard, as well as the most affected sex and age group.

Given the fact that this is a breed with high aesthetic expectations, many owners and even professionals end up considering only the aesthetic issue of alopecia. However, the fur of these animals plays a fundamental role in thermoregulation and protection from ultraviolet rays, and when the skin is secondarily exposed to alopecia, it can more easily acquire secondary infections and dryness (PASSATUTTO E JÚNIOR, 2021), and must be treated with the aim of restoring the skin and fur.

REFERENCES

1. Modolo, J. R., Langoni, H., Padovani, C. R., Shimabukuro, F. H., Mendonça, A. O., Victoria, C., & Silva, W. B. (2006). Investigação soroepidemiológica de leptospirose canina na área territorial urbana de Botucatu, São Paulo, Brasil. *Brazilian Journal of Veterinary Research and Animal Science*, 43(5), 598-604.
2. Baptista, A. B. (2018). Avaliação do microagulhamento na terapêutica da alopecia X em cães da raça Spitz Alemão (Dissertação de mestrado, Universidade Santo Amaro, São Paulo).
3. Passatutto, M. V., & Almeida Junior, S. T. de A. (2021). Alopecia X em cães da raça Spitz Alemão. *Revista Agroveterinária do Sul de Minas*, 3(1), 40-60.
4. Horta, G. F., et al. (2021). Aspectos clínicos e etiológicos da alopecia X em cães: Uma revisão de literatura. *Revista de Educação Continuada em Medicina Veterinária e Zootecnia do CRMV-SP*, 19(1). <https://doi.org/10.36440/recmvz.v19i1.38182>
5. Mondes, P. H. de L., & Tamura, E. K. (2021). Melatonina em animais de companhia: Uma revisão de literatura. *Ensaio e Ciência*, 25(5 Esp.), 671-681.
6. Carvalho, J. C., et al. (2023). Técnica de microagulhamento para tratamento da alopecia X em cães: Relato de dois casos. *Revista Brasileira de Higiene e Sanidade Animal*, 17(2), 1-9.
7. Mello, F. L. de A., et al. (2022). Microagulhamento associado a orquiectomia como tratamento de alopecia X em caso da raça Spitz Alemão. *Pubvet*, 16(11), a1264, 1-9.
8. Talarico, C. P., et al. (2020). Alopecia X: Relato de caso. (Trabalho de conclusão de residência, Universidade de Uberlândia, Uberlândia, MG).
9. Venâncio, J., et al. (2016). Alopecia X: A evolução da etiopatogenia. *Revista de Educação Continuada em Dermatologia e Alergologia Veterinária*.
10. Gondim, A., & Araújo, A. (2020). Alopecia X em cães: Revisão. *Pubvet*, 14(5), a573, 1-8.
11. Adamo, I. (n.d.). Alopecia X: Uma revisão de literatura. (Trabalho de conclusão de curso).
12. Moraes, C. C. G., Megid, J., Souza, L. C., & Crocci, A. J. (2002). Prevalência da brucelose canina na microrregião da Serra de Botucatu, São Paulo, Brasil. *Arquivos do Instituto Biológico*, 69(2), 7-10.
13. Moraes, L. A., Laranja, H. F., Vieira, D. K., Lopes, S. P., Freaza, A., Melo, G. P., & Penchel, V. (2002b). Identificação de cães potencialmente transmissores de brucelose na Zona Oeste da cidade do Rio de Janeiro. *Revista Brasileira de Ciência Veterinária*, 9(3), 154-157.
14. Moraes, M., & Costa, P. (2007). Parvoviridae. In E. F. Flores (Ed.), *Virologia veterinária* (1st ed., p. 382). Ed. da UFSM.

15. Nakamura, M., Tohya, Y., Miyazawa, T., Mochizuki, M., Phung, H. T. T., Nguyen, N. H., Huynh, L. M. T., Nguyen, L. T., Nguyen, P. N., Nguyen, P. V., & Akashi, H. (2004). A novel antigenic variant of canine parvovirus from a Vietnamese dog. *Archives of Virology*, 149, 2261-2269.
16. OIE – World Organization for Animal Health. (2008). Manual of diagnostic test and vaccines for terrestrial animals. Available at: http://www.oie.int/fileadmin/Home/eng/Health_standards/tahm/2.01.09_LEPTO.pdf. Accessed on: November 6, 2013.
17. Pratelli, A. L., Cavalli, A., Martella, V., Tempesta, M., Decaro, N., Carmichael, L. E., & Buonavoglia, C. (2001). Canine parvovirus (CPV) vaccination: Comparison of neutralizing antibody responses in pups after inoculation with CPV2 or CPV2b modified live virus vaccine. *Clinical and Diagnostic Laboratory Immunology*, 8(3), 612-615.
18. Querino, A. M. V., Delbem, Á. C. B., Oliveira, R. C., Silva, F. G., Müller, E. E., Freire, R. L., & Freitas, J. C. (2003). Fatores de risco associados à leptospirose em cães do município de Londrina-PR. *Semina: Ciências Agrárias*, 24(1), 27-34.
19. Reis, C. B. M., Hoffmann, R. C., Santos, R. S., Turri, R. J. G., & Oriani, M. R. G. (2008). Pesquisa de anticorpos anti-Brucella canis e anti-Brucella abortus em cães errantes da cidade de São João da Boa Vista, Estado de São Paulo, Brasil (2002-2003). *Brazilian Journal of Veterinary Research and Animal Science*, 45(1), 32-34.
20. Santos, P., Pinto, A. M. V., Garcia, R. C. N. C., Labarthes, N. V., Oliveira, L. H. S., & Silva, F. G. (1997). Padronização de reagentes e métodos utilizados na técnica de hemaglutinação para o diagnóstico laboratorial da parvovirose canina. *Revista Brasileira de Ciência Veterinária*, 4(3), 111-115.
21. Scanziani, E., Calcaterra, S., & Tagliabue, S. (1994). Serologic findings in cases of acute leptospirosis in the dog. *Journal of Small Animal Practice*, 35, 257-260.
22. Santa Rosa, C. A. (1970). Diagnóstico laboratorial das leptospiroses. *Revista de Microbiologia*, 1(2), 97-109.
23. Senda, M., Hirayama, N., Yamamoto, H., & Kurata, K. (1986). An improved hemagglutination test for study of canine parvovirus. *Veterinary Microbiology*, 12, 1-6.
24. Strottmann, D. M., Scortegagna, G., Kreutz, L. C., Barcellos, L. J. G., Frandoloso, R., & Anziliero, D. (2008). Diagnóstico e estudo sorológico da infecção pelo parvovirus canino em cães de Passo Fundo, Rio Grande do Sul, Brasil. *Ciência Rural*, 38(2), 400-405.
25. Sulzer, C. R., & Jones, W. L. (1973). Evaluation of a hemagglutination test for human leptospirosis. *Applied Microbiology*, 26(5), 655-657.
26. Truyen, U., Gruenberg, A., Chang, S. F., Obermaier, B., Veijalainen, P., & Parrish, C. R. (1995). Evolution of the feline-subgroup parvoviruses and the control of canine host range in vivo. *Journal of Virology*, 69(9), 4702-4710.
27. Vargas, A. C., Lazzari, A., Dutra, V., & Poester, F. (1996). Brucelose Canina: Relato de caso. *Ciência Rural*, 26(2).



28. World Health Organization (WHO). (1967). Current problems in leptospirosis research: Report of a WHO expert group (Technical Report Series, No. 380).
29. World Health Organization (WHO). (2003). Human leptospirosis: Guidance for diagnosis, surveillance and control. Available at: http://whqlibdoc.who.int/hq/2003/WHO_CDS_CSR_EPH_2002.23.pdf. Accessed on: June 6, 2016.