



Minimally invasive animal model for bone implant in swine

Modelo animal minimamente invasivos para implante ósseo em suínos

DOI: 10.56238/isevjhv2n4-035

Receipt of originals: 10/08/2023

Acceptance for publication: 31/08/2023

Marco Antonio Schueda

Professor and Coordinator of the Faculty of Medicine of the University of Contestado

Email: schueda.sc@gmail.com

Thiago Fuchs

Professor and Coordinator of the Faculty of Veterinary Medicine of the University of Contestado

Email: thiago.fuchs@professor.unc.br

Lara Thaís Marcon

Graduating student of the Faculty of Medicine of the University of Contestado,

Email: lara.marcon@aluno.unc.br

ABSTRACT

Objective: The main objective of this study was to develop a minimally invasive Animal Model that could accommodate evaluation experiments for cortico-spongy implants in the areas of Orthopedics, Dentistry and Neurology. **Methodology:** On the anteromedial surface of the proximal third of the Tibia of Swine we have a cortico-spongy area basically subcutaneous. This region was ideal for this purpose. **Results and discussions:** The pig is already a known animal to test biomaterials on bones because it has similarities its bone regeneration rate (1.2 and 1.5 mm/d) comparable to that of humans (1.0 and 1.5 mm/d) **Conclusion:** It was possible to format the Animal Model that proved to be simple and reproducible to perform.

Keywords: Porcine animal model, Spongy cortical bone, Proximal tibia.

1 INTRODUCTION

With the evolution of science and technology, especially in the field of medicine, the use of Animal Models for the evolution of techniques and treatments have become of paramount importance. Galen (129-210 A.D.), forerunner of experimental medical research with the use of animals inspired adherents to this plan of study, but it was Claude Bernard in 1865 who launched the principles of its use in the work "Introduction to the Study of Experimental Medicine" establishing the rules and principles for such. Since then, the significance of the use of animal models has gained greater attention and relevance¹.

In orthopedics, an anatomy with greater proximity to the human is necessary, in addition to the similar pathophysiological and histological composition to be able to present relevant results².



Several animal test models, such as rats/mice^{3,4,5}, rabbits^{3,6,7}, dogs^{3,8,9}, sheep^{3,10,11}, goats^{3,12,13} and pigs^{3,14,15}, were developed to simulate environment and physical conditions by testing the biocompatibility of substitute biomaterials for human bones "*in vivo*". In order to simulate various orthopedic situations, many sites of defects were explored, such as calvary^{3,16,17}, femur/tibia^{3,18,19} and ulna^{3,20,21,22}.

Factors should be considered when selecting a specific animal species as a test model. First, the animal model chosen must clearly demonstrate significant physiological and pathophysiological analogies compared to humans. Secondly, it should evaluate whether it is possible to operate and observe a multiplicity of study objects after surgery over a period of time²³. Other selection criteria include acquisition and care costs, availability of the animal, acceptability by society, tolerance to captivity and ease of housing²⁴. According to the international standard, we should also consider the size of the implant test specimens, number of implants per animal, intended duration of the test and possible differences between species when correlated with biological responses²⁵.

In the present study, pigs were preferred to be used as anatomical models. This choice was initially due to the greater morphological/anatomical similarity with man, in addition to the ease of releasing them for *in vivo* study. Followed by the choice of pigs as an animal model, the need for anatomical regions whose histology presented cortico-spongy regions was specified. Such histology is present in metaphyses of long bones, such as the femur and tibia. We limited the study to the tibia because it has a triangular shape and in the anteromedial region of its proximal third is basically subcutaneous, thus facilitating its approach. There is already an animal model that contemplates these requirements²⁶, but with a bloodier approach, by incision that accesses skin, subcutaneous, periosteum and bone leaves the surgical time and recovery more prolonged.

It will be presented in this work a new procedure that will facilitate the evaluation of biocompatibility and recovery after cortico-spongy implants in Medicine and Veterinary Medicine in the specialties of Orthopedics, Traumatology, Dentistry and Neurology in a minimally invasive way.

2 MATERIAL AND METHODS

Study carried out at the Veterinary Surgical Center of the Mafra Campus of UNC – Fundação Universidade do Contestado (Figures 1 A and 1 B)

Figure 1 A – UNC Veterinary Surgical Center (Campus Mafra - SC)

Figure 1 B – Procedure Room with specific lighting, instrumentation and anesthesia equipment



Preparation and arrangement of materials and surgical specimen (Figure 2)

Figure 2 – Prepared materials and part

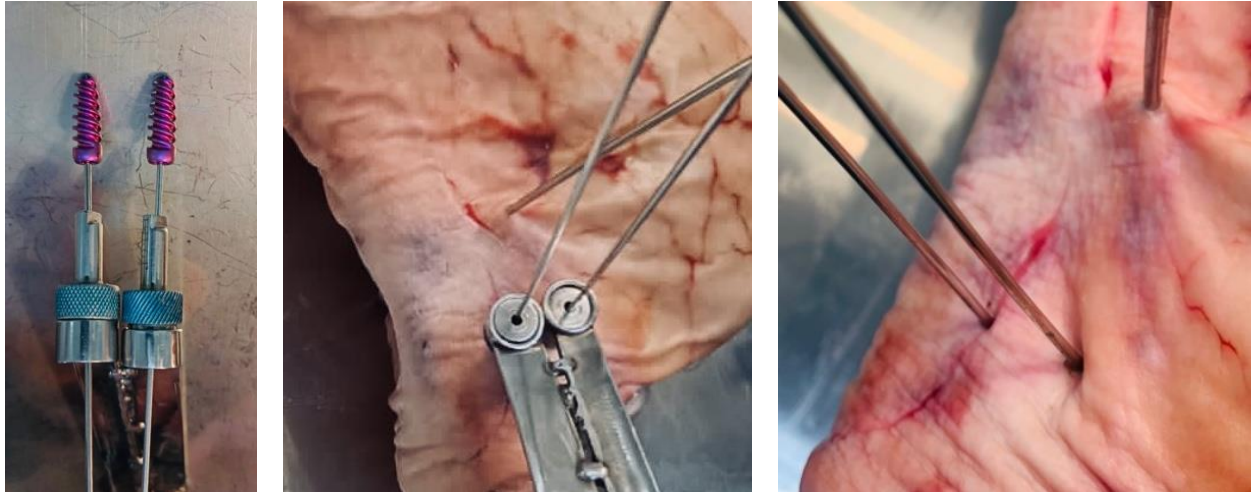


After localization of the knee joint with Kirschner 2.0 thread, the instrument is positioned on the anteromedial surface of the proximal tibia and the skin, subcutaneous, periosteal, first cortical and spongy skin are perforated until it is fixed in the second cortical tibia with Kirschner wire 1,5. (Figures 3 A, B and C)

Figure 3 A – Instrumental created for passage of guide wires and introduction of interference screws to allow minimally invasive technique

Figure 3 B – After passage of the Kirschner Wire 2.0 in the knee joint, the guide wires are passed through the instrumental

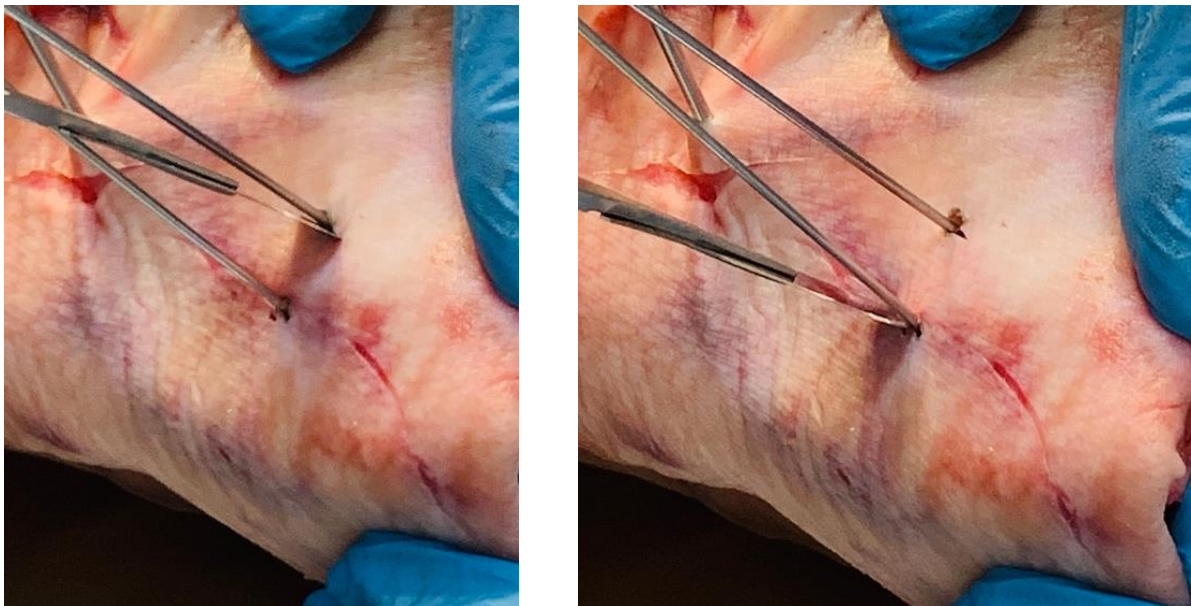Figure 3 C – Kirschner 1.5 parallel guide wires positioned surpassing the first and fixing it in the second cortical



With scalpel handle 4 with blade 23 incline laterally to the wire for 1 cm. (Figures 4 A and 4 B)

Figure 4 A – incision of 1 cm laterally to the first guide wire

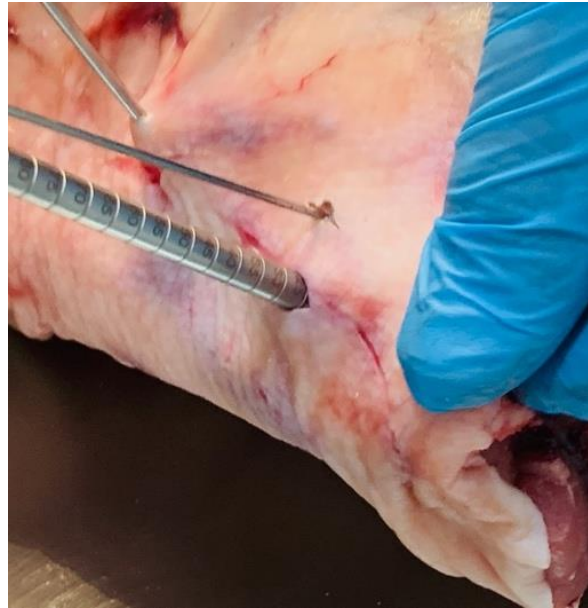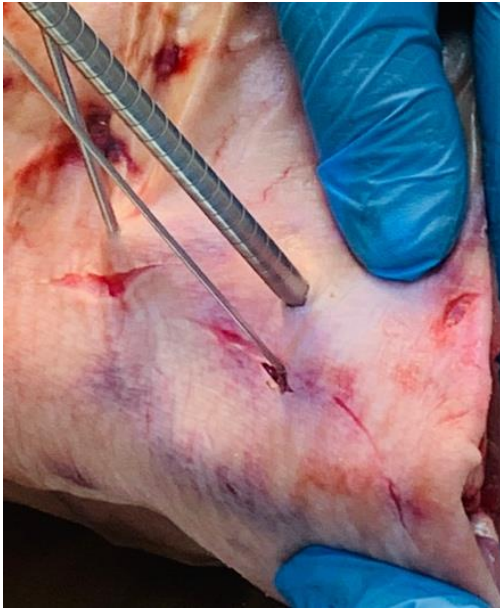Figure 4 B – incision of 1 cm laterally to the second guide wire



We then drilled with a 6 mm cannulated drill for a depth of 20 mm in the proximal tibia. (Figures 5 A and 5 B)

Figure 5 A – Perforation with 6 mm cannulated drill following the first guide wire by 20 mm in the proximal tibia

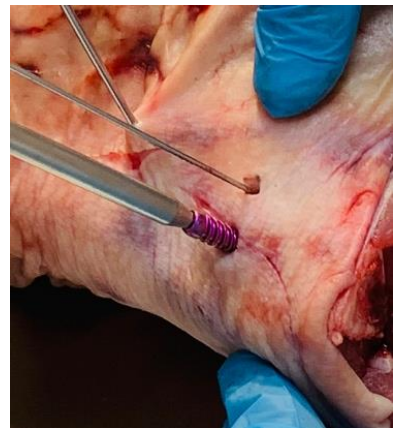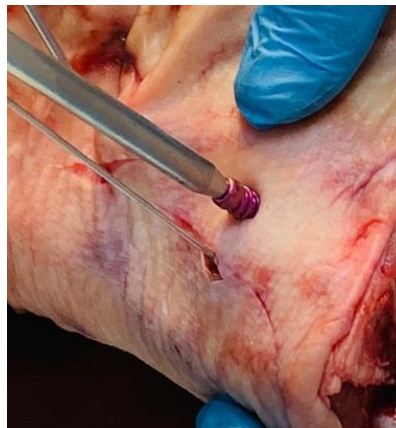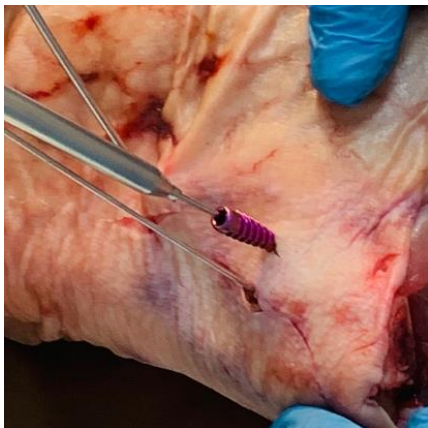Figure 5 B – Perforation with 6 mm cannulated drill following the second guide wire by 20 mm in the proximal tibia



Following the guide wire, the bone screw of 7 mm x 20 mm is inserted, turning until it aligns with the cortical surface of the tibia. (Figures 6 A and 6 B)

Figure 6 A/B – Screw 70X20 mm implant following the first guide wire until it aligns with the cortical surface of the Tibia

Figure 6 C – Screw 70X20 mm implant following the second guide wire until it aligns with the cortical surface of the Tibia

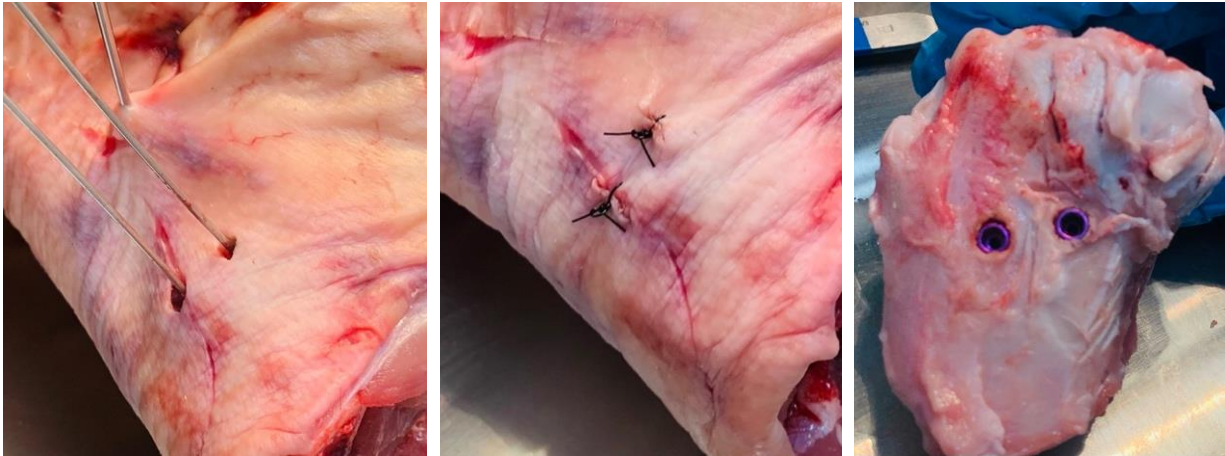


After fixation of the screws, the intra-articular and bone wires are performed and skin is sutured with single stitches of mononylon 2.0. (Figures 7 A and 7 B)

Figure 7 A – Joint and bone wires present and being removed

Figure 7 B – Skin suture

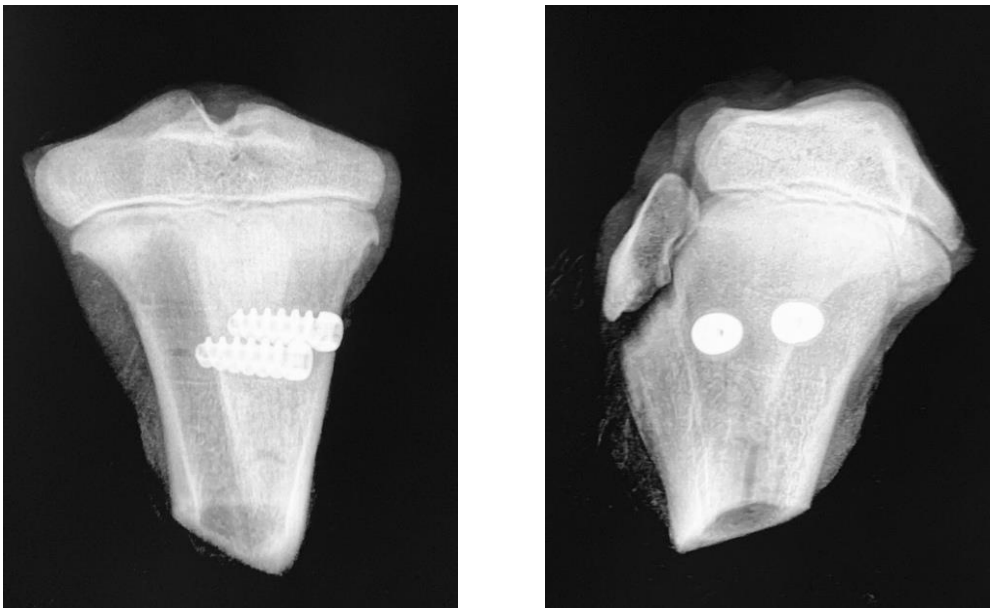
Figure 7 C – Positioning of the screws in the proximal tibia



A post-procedure radiographic study was performed to visualize the positioning of the implants. (Figures 8 A in Antero Posterior and 8 B in Profile)

Figure 8 A – Radiographic study in PA (Antero Posterior) of the swine tibia

Figure 8 B – Radiographic study in Porcine Tibia Profile



3 RESULTS, DISCUSSIONS AND THEORETICAL FRAMEWORK

Pigs are considered close representative models with regard to bone anatomy, morphology, healing capacity, remodeling, mineral density and concentration^{27,28}. Similarities were found in the diameter of the cross-section of the femur and in the area between humans and pigs²⁹. Pigs



have a lamellar bone structure similar to that of humans³⁰. However, pigs have a denser trabecular network, considered intricate. They are difficult to handle, noisy and aggressive; therefore, pigs are often neglected in favor of more receptive species, such as sheep and goats^{31,32}. In addition, the length of the tibias and femurs in pigs is relatively small, which cannot meet the special needs of human implants. The pig was the animal chosen for critical size defect models to test bone substitute biomaterials because its bone regeneration rate (1.2 and 1.5 mm/d) is comparable to that of humans (1.0 and 1.5 mm/d)²².

Commercial pigs are generally considered undesirable for orthopedic research because of their high growth rates and body weight. It should be noted that, the development of mini-pigs and micropigs has overcome this problem to some extent. However, in our region, it is easy to obtain and manage these animals, when compared to the others, making the application of this Animal Model much easier.

4 CONCLUSION

It was possible to format the Animal Model in pigs for spongy cortico implants of simple, reproducible and minimally invasive execution.



REFERENCES

- Rebollo RA.; O legado Hipocrático e sua fortuna no período greco-romano: de Cós a Galeno. *Scientiae Studia* [online]. 2006; v. 4, n.1; 45-81
- Fagundes DJ. e Taha MO.: Modelo animal de doença: critérios de escolha e espécies de animais de uso corrente. *Acta Cirúrgica Brasileira* [online]. 2004; v.19, n.1.
- Ye L., Shu-Kui C., Long L., Ling Q., Xin-Luan W., Yu-Xiao L.; Bone defect animal models for testing efficacy of bone substitute biomaterials. review article *Journal of Orthopaedic Translation* (2015) 3, 95-104
- Zwingenberger S, Niederlohmann E, Vater C, Rammelt S, Matthys R, Bernhardt R, et al. Establishment of a femoral critical-size bone defect model in immunodeficient mice. *J Surg Res* 2013; 181; 7-14.
- Bateman JP, Safadi FF, Susin C, Wikesjo UM. Exploratory study on the effect of osteoactivin on bone formation in the rat critical-size calvarial defect model. *J Periodontal Res* 2012; 47: 243-247.
- Zhang X, Cai Q, Liu H, Heng BC, Peng H, Song Y, et al. Osteoconductive effectiveness of bone graft derived from antler cancellous bone: an experimental study in the rabbit mandible defect model. *Int J Oral Maxillofac Surg* 2012;41: 1330-1337.
- Schneider G, Blechschmidt K, Linde D, Litschko P, Korbs T, Beleites E. Bone regeneration with glass ceramic implants and calcium phosphate cements in a rabbit cranial defect model. *J Mater Sci Mater Med* 2010; 21: 2853-2859.
- Yano K, Namikawa T, Uemura T, Hoshino M, Wakitani S, Takaoka K, et al. Regenerative repair of bone defects with osteoinductive hydroxyapatite fabricated to match the defect and implanted with combined use of computer-aided design, computer-aided manufacturing, and computer-assisted surgery systems: a feasibility study in a canine model. *J Orthop Sci* 2012; 17: 484-489.
- Takigami H, Kumagai K, Latson L, Togawa D, Bauer T, Powell K, et al. Bone formation following OP-1 implanta- tion is improved by addition of autogenous bone marrow cells in a canine femur defect model. *J Orthop Res* 2007; 25:1333-1342.
- Yang HL, Zhu XS, Chen L, Chen CM, Mangham DC, Coulton LA, et al. Bone healing response to a synthetic calcium sulfate/beta-tricalcium phosphate graft material in a sheep vertebral body defect model. *J Biomed Mater Res B Appl Biomater* 2012; 100: 1911-1921.
- Reichert JC, Epari DR, Wullschleger ME, Saifzadeh S, Steck R, Lienau J, et al. Establishment of a preclinical ovine model for tibial segmental bone defect repair by applying bone tissue engineering strategies. *Tissue Eng Part B Rev* 2010;16: 93-104.
- Lippens E, Vertenten G, Girones J, Declercq H, Saunders J, Luyten J, et al. Evaluation of bone regeneration with an injectable, in situ polymerizable Pluronic F127 hydrogel derivative combined with autologous mesenchymal stem cells in a goat tibia defect model. *Tissue Eng Part A* 2010;16: 617-627.



Yu D, Li Q, Mu X, Chang T, Xiong Z. Bone regeneration of critical calvarial defect in goat model by PLGA/TCP/rhBMP-2 scaffolds prepared by low-temperature rapid-prototyping technology. *Int J Oral Maxillofac Surg* 2008; 37: 929-934.

Wehrhan F, Amann K, Molenberg A, Lutz R, Neukam FW, Schlegel KA. PEG matrix enables cell-mediated local BMP-2 gene delivery and increased bone formation in a porcine critical size defect model of craniofacial bone regeneration. *Clin Oral Implants Res* 2012; 23: 805-813.

Springer IN, Acil Y, Kuchenbecker S, Bolte H, Warnke PH, Abboud M, et al. Bone graft versus BMP-7 in a critical size defect cranioplasty in a growing infant model. *Bone* 2005; 37:563-569.

Rahman CV, Ben-David D, Dhillon A, Kuhn G, Gould TW, Muller R, et al. Controlled release of BMP-2 from a sintered polymer scaffold enhances bone repair in a mouse calvarial defect model. *J Tissue Eng Regen Med* 2014; 8: 59-66.

Das A, Tanner S, Barker DA, Green D, Botchwey EA. Delivery of S1P receptor-targeted drugs via biodegradable polymer scaffolds enhances bone regeneration in a critical size cranial defect. *J Biomed Mater Res A* 2014; 102:1210-18.

Li R, Nauth A, Li C, Qamirani E, Atesok K, Schemitsch EH. Expression of VEGF gene isoforms in a rat segmental bone defect model treated with EPCs. *J Orthop Trauma* 2012; 26: 689-92.

Cheng C, Alt V, Dimitrakopoulou-Strauss A, Pan L, Thormann U, Schnettler R, et al. Evaluation of new bone formation in normal and osteoporotic rats with a 3-mm femur defect: functional assessment with dynamic PET-CT (dPET-CT) using 2-deoxy-2-[(18)F]fluoro-D-glucose ((18)F-FDG) and (18)F-fluoride. *Mol Imaging Biol* 2013; 15: 336-44.

Mohan BG, Shenoy SJ, Babu SS, Varma HK, John A. Strontium calcium phosphate for the repair of leporine (*Oryctolagus cuniculus*) ulna segmental defect. *J Biomed Mater Res A* 2013; 101: 261-71.

Kim A, Kim DH, Song HR, Kang WH, Kim HJ, Lim HC, et al. Repair of rabbit ulna segmental bone defect using freshly isolated adipose-derived stromal vascular fraction. *Cytotherapy* 2012; 14: 296-305.

Schlegel KA, Lang FJ, Donath K, Kulow JT, Wiltfang J. The monocortical critical size bone defect as an alternative experimental model in testing bone substitute materials. *Oral Surg Oral Med Oral Pathol Oral Radiol Endod* 2006; 102: 7-13.

Liebschner MA. Biomechanical considerations of animal models used in tissue engineering of bone. *Biomaterials* 2004; 25: 1697-1714.

Pearce AI, Richards RG, Milz S, Schneider E, Pearce SG. Animal models for implant biomaterial research in bone: a review. *Eur Cell Mater* 2007; 13: 1-10.

Upman PJ. ISO 10993-6: test for local effects after implantation. *Bonezone* 2006; 5: 50-2.

Schueda MA, Fuchs T, Belo WM, Marcon LT, Bay LD, Heidemann F. Modelo animal para implante ósseo em suínos. *Brazilian Journal of Development*, v.9, n.1, p. 3936-3949, jan., 2023



Thorwarth M, Schultze-Mosgau S, Kessler P, Wiltfang J, Schlegel KA. Bone regeneration in osseous defects using a resorbable nanoparticulate hydroxyapatite. *J Oral Maxillofac Surg* 2005; 63: 1626-33.

Aerssens J, Boonen S, Lowet G, Dequeker J. Interspecies differences in bone composition, density, and quality: potential implications for in vivo bone research. *Endocrinology* 1998; 139: 663-670.

Raab DM, Crenshaw TD, Kimmel DB, Smith EL. A histo-morphometric study of cortical bone activity during increased weight-bearing exercise. *J Bone Min Res* 1991;6: 741-749.

Mosekilde L, Kragstrup J, Richards A. Compressive strength, ash weight, and volume of vertebral trabecular bone in experimental fluorosis in pigs. *Calcif Tissue Int* 1987; 40: 318-322.

Mosekilde L, Weisbrode SE, Safron JA, Stills HF, Jankowsky ML, Ebert DC, et al. Calcium-restricted ovariectomized Sinclair S-1 minipigs: an animal model of osteopenia and trabecular plate perforation. *Bone* 1993; 14: 379-382.

Swindle MM, Smith AC, Hepburn BJ. Swine as models in experimental surgery. *J Invest Surg* 1988; 1: 65-79.